



PATIENT

Snookie Peters

SPECIES

Canine

BREED

Mix

SEX

Female Spayed

AGE

12 years

WEIGHT

63.1lbs

INTERPRETED BY

Maggie Machen
Lamy, DVM
DACVIM (Cardiology)

**IMAGING
PERFORMED BY**

Pamela Harrigan,
RDCS

HOSPITAL NAME

Mass Veterinary
Specialty Services

REFERRING VET

Dr. Masloski

INVOICE

20740

DATE

8/25/21

PRESENTING CLINICAL SIGNS

History: Sookie was recently seen for a cough and some trouble breathing. Thoracic radiographs taken at that time (July) revealed a soft tissue opacity in the region of the aortic arch Ddx: prominent aortic arch from systemic hypertension, aortic stenosis, vs heart base mass. The heart and vasculature were noted to be normal with a diffuse broncho-interstitial pattern noted throughout her lung fields. At this point, Sookie appears to be doing a bit better with some raspiness noted to her breathing sometimes noted an only an occasional cough. She is presently eating well with no noted S/V/D/PU/PD. She was given trazadone 200mg at midnight and again at noon (now 2:35) for her exam. On exam, NSR no murmurs noted PSS lung fields clear. *Sedated with propofol.

ECHOCARDIOGRAM FINDINGS

2D, m-mode, color flow and Doppler imaging is available.

Left ventricle: The LV diameter is decreased with adequate myocardial function. LV wall thicknesses are mildly increased.

Left atrium: The left atrium is normal.

Mitral valve: The mitral valve is normal with no prolapse into the left atrial lumen. No mitral regurgitation.

Aortic valve/Aorta: The aortic valve appears trileaflet with normal mobility. Mildly thickened leaflets. Normal aortic outflow velocity. The sub-aortic region appears decreased comparatively; however, this is likely a relative stenosis. Trace/mild aortic insufficiency. Normal velocity. The ascending aorta and aortic arch are markedly dilated (max 3.0cm) with tapering in the descending region. Mild dilation of the aortic root.

Right ventricle: Normal right ventricular diameter and morphology indicating no overt evidence of pulmonary arterial hypertension.

Right atrium: Normal RA dimension.

Tricuspid valve: The tricuspid valve appears normal with no tricuspid regurgitation.

Pulmonic valve/Pulmonary artery: The pulmonic valve is normal in morphology and mobility. No pulmonic insufficiency. Normal RVOT velocity; laminar flow.

Pericardium/other: No pericardial or pleural effusion noted. No obvious cardiac masses

Heart rhythm: ECG reveals a sinus rhythm with an average HR of 100bpm.

2-Dimensional Measurements

Ao diam (cm)	3.1
LA diam (cm)	2.7
LA:Ao (Swe)	0.9
IVS thickness (cm)	1.4
LVID diastole (cm)	2.75
PW thickness (cm)	1.2
LVID systole (cm)	1.9
FS (%)	31

Doppler Measurements

PV Vmax (m/s)	0.67
AoV Vmax (m/s)	1.6
MR Vmax (m/s)	NA
TR Vmax (m/s)	NA
TR PG (mmHg)	NA



PATIENT

Snookie Peters

SPECIES

Canine

BREED

Mix

SEX

Female Spayed

AGE

12 years

WEIGHT

63.1lbs

INTERPRETED BY

Maggie Machen
Lamy, DVM
DACVIM (Cardiology)

IMAGING PERFORMED BY

Pamela Harrigan,
RDCS

HOSPITAL NAME

Mass Veterinary
Specialty Services

REFERRING VET

Dr. Masloski

INVOICE

20740

DATE

8/25/21

INTERPRETATION OF THE FINDINGS

The most striking finding is a markedly dilated ascending aorta and aortic arch. The aortic valve is mildly thickened with a small leak, which should be monitored going forward. This in total is quite an unusual finding in small animals. Rule outs for this finding include systemic hypertension (unable to obtain a BP), coarctation of the aorta (distal narrowing), annuloaortic ectasia (dilation due to Marfan-like syndrome), aortic dissection (unlikely), normal variant, other. While post-stenotic dilation is possible with severe stenosis, there is no obvious stenosis seen here. **A screening BP is highly recommended on both the forelimbs and pelvic limbs to assess for discrepancy.** In a senior dog this is unusual to see as a new finding, although not impossible if chest radiographs have not been performed previously. The LV also appears decreased in dimension with mild hypertrophy, which may be a real finding or may be pseudohypertrophy with volume changes. Baseline lab work may be useful if not recently performed. Regardless, the patient may have increased risk for aortic aneurysm/rupture and sudden death in the future. Advanced imaging should be considered, to rule out the listed abnormalities and assess risk. The possibility of a normal variant remains.

Even with these findings, it is unlikely that this is related to the reported cough. Continued respiratory evaluation/treatment is recommended as dictated by symptom persistence.

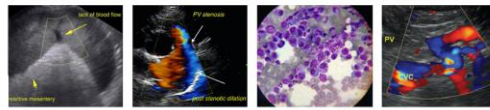
Prognosis is guarded prior to further evaluation.

RECOMMENDATIONS

- Given these findings, no cardiac medications are clearly indicated.
- Highly recommend obtaining a blood pressure and lab work in this patient.
- Consider referral for advanced imaging if elected.
- Continue to treat the cough symptomatically with primary airway causes most likely.
- Monitor for development of labored breathing, exercise intolerance or collapse episodes.
- Mild exercise restriction is advised.
- Elective anesthesia is not advised prior to further evaluation.

PLAN

- Recommend recheck echocardiogram pending results of further evaluation.



PATIENT

Snookie Peters

SPECIES

Canine

BREED

Mix

SEX

Female Spayed

AGE

12 years

WEIGHT

63.1lbs

INTERPRETED BY

Maggie Machen
Lamy, DVM
DACVIM (Cardiology)

**IMAGING
PERFORMED BY**

Pamela Harrigan,
RDCS

HOSPITAL NAME

Mass Veterinary
Specialty Services

REFERRING VET

Dr. Masloski

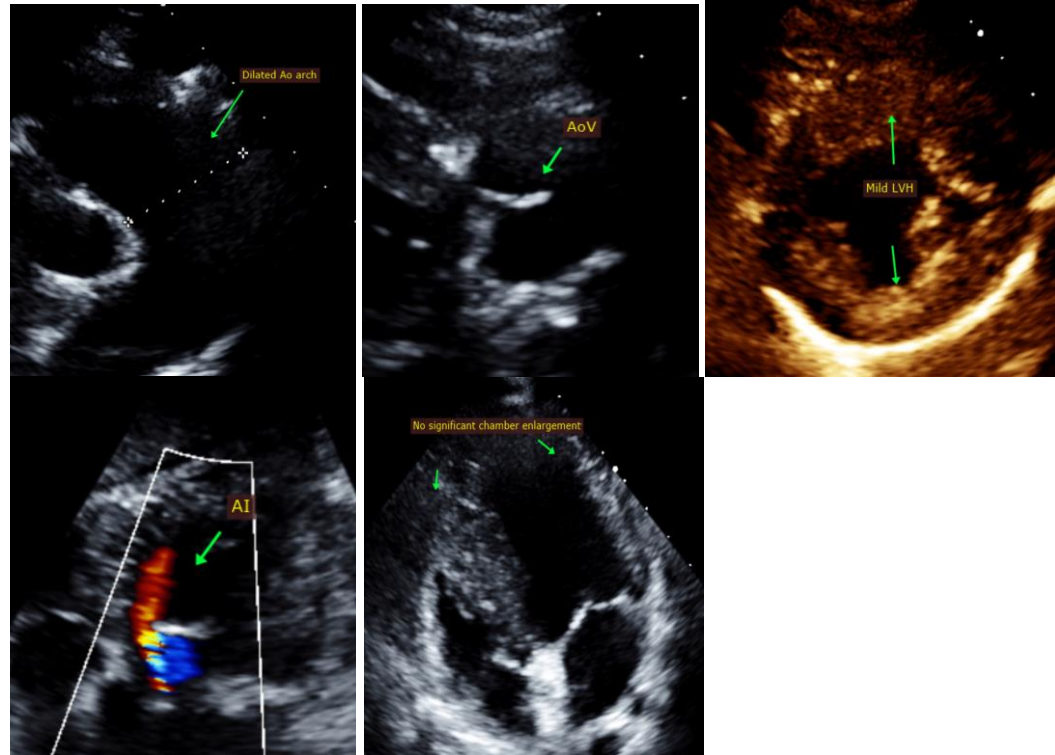
INVOICE

20740

DATE

8/25/21

IMAGES



The information and recommendations provided are based on the images presented by the referring veterinarian. No evaluation can be communicated regarding pathology that was not visible in the image/video clips provided.

Thank you for this referral. This report was generated using transcription software, and minor dictation errors may be present. If the clinical or image interpretation does not parallel your findings or if I can be of any further assistance, please contact me.

Maggie Machen Lamy, DVM
Diplomate of the American College of Veterinary Internal Medicine (Cardiology)
info@sonopath.com

Echocardiogram performed by: Pamela Harrigan, RDCS
Pet Animal Ultrasound Service (4paus.com)